



Available online at <http://scik.org>

J. Math. Comput. Sci. 11 (2021), No. 2, 1997-2014

<https://doi.org/10.28919/jmcs/5402>

ISSN: 1927-5307

## **NOVEL FEATURE SET FOR AUTOMATIC ASSESSMENT AND CLASSIFICATION OF BREAST TUMOR THROUGH BACK PROPAGATION ARTIFICIAL NEURAL NETWORK**

S.V. SHWETHA<sup>1</sup>, L. DHARMANNA<sup>1,\*</sup>, BASAVARAJ S. ANAMI<sup>2</sup>

<sup>1</sup>Dept. of ISE, SDMIT, Ujire-574240, India

<sup>2</sup>KLEIT, Hubballi-580030, India

Copyright © 2021 the author(s). This is an open access article distributed under the Creative Commons Attribution License, which permits unrestricted use, distribution, and reproduction in any medium, provided the original work is properly cited.

**Abstract:** Breast cancer is a deadly disease having high mortality rate from several years. It is second and fourth leading disease in the world and India respectively as per the WHO. The conventional techniques are unsupervised to classify breast cancer that involves erroneous, laborious and demanding inevitable presence of clinician. It is also experimented on small dataset and the accuracy of the previous classifier methods was unsatisfactory. To overcome these problems, we have experimented on large dataset and extracted several features such as area, convex area, bounding box, eccentricity, orientation, solidity, and perimeter, contour based fractal dimension etc. These feature set describes the size and geometrical shape of the tumor. The increase in feature set leads to increase in the accuracy of the classification. The automatic classification is based on multilayer back propagation artificial neural networks (ANN) algorithm. The breast cancer tumors have an important clue in its boundary, hence analysis of that plays a vital role for better identification of disease. The dataset is split into training and testing data on an around 1700 samples using 80-20 rule with different neural network architectures. Hence the accuracy of 98.11% has been achieved in the classification rate. The successful classification depends on the quality of the enhanced mammograms, localization of tumor and accurate segmentation. The image samples from MIAS, DDSM and local hospitals had been involved in the experiment.

---

\*Corresponding author

E-mail address: [dharmannasdmit@gmail.com](mailto:dharmannasdmit@gmail.com)

Received January 8, 2021

**Keywords:** ANN classifier; feed forward back propagation; contour, malignant; benign, solidity; eccentricity; orientation.

**2010 AMS Subject Classification:** 92B05.

## 1. INTRODUCTION

Out of overall cancer mortality rate the breast cancer is the 38% as per the WHO statistics. As the diagnosis is dependent on the oncologist that is fewer in number, the mortality rate is high. The conventional system could be upgraded by the automatic method of classification using Neural Networks. Artificial neural network learning provides an approach for learning decimal data function over discrete data and analog data attributes in a way that is very strong against to noise in the training sample. The back propagation method is the most usual leading network technique and had been successfully adapted to classify breast cancer medical images and several learning task like automatic vehicle driving, handwriting recognition, controlling robots. In the figure 1, the hypothesis space considered by the back propagation technique is the space of all function that can be represented by assigning weights to the given fixed network of interconnected network units.

The general architecture of ANN has three layers such as input, hidden and output layers and two biasing units one for hidden layer and one for output layer as shown in the figure 1. The network of required size are capable of simulating a enough space of non linear results, creating feed forward network a better choice for learning analog and discrete function whose general form is not known in advance.

Back propagation method finds the space of possible hypothesis using gradient descent to repetitively minimize the error in the network and fits to the training samples. Gradient descent function converges to a recompilation of weights in the training error with respect to the network weights.

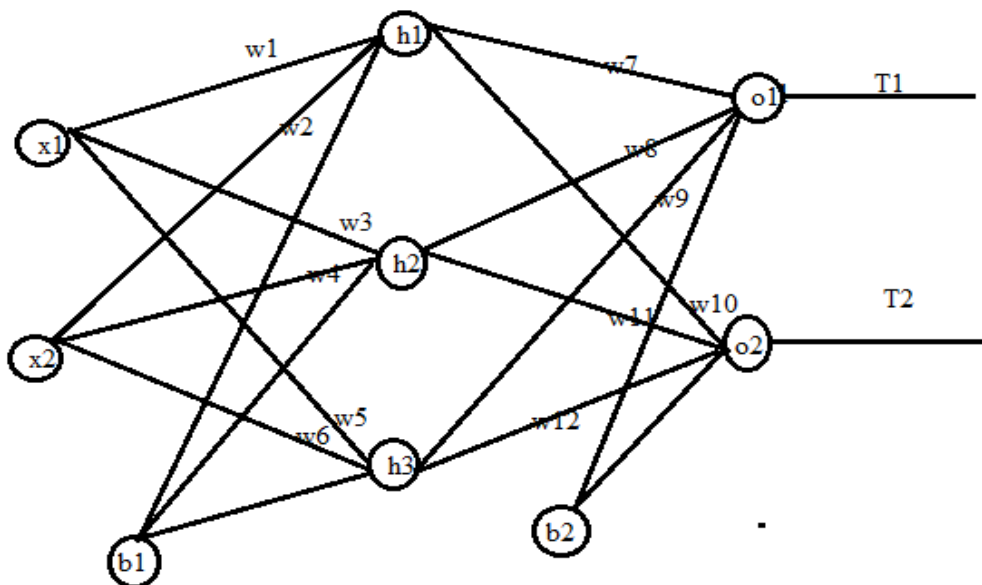


Fig.1. Artificial Neural Network with backpropagation

Breast cancer may be appeared as tumor commonly with an irregular shape as shown in fig, 2 and the cancer tumor's contour is more irregular than normal tumor. The detailed description of the benign and malignant mammograms had been explained in the paper entitled in "Automatic Detection And Classification Of Malignant Tumor In Mammograms Image Using Image Feature Fractal Dimension" [14]. The images courtesy is for MIAS, DDSM databases.

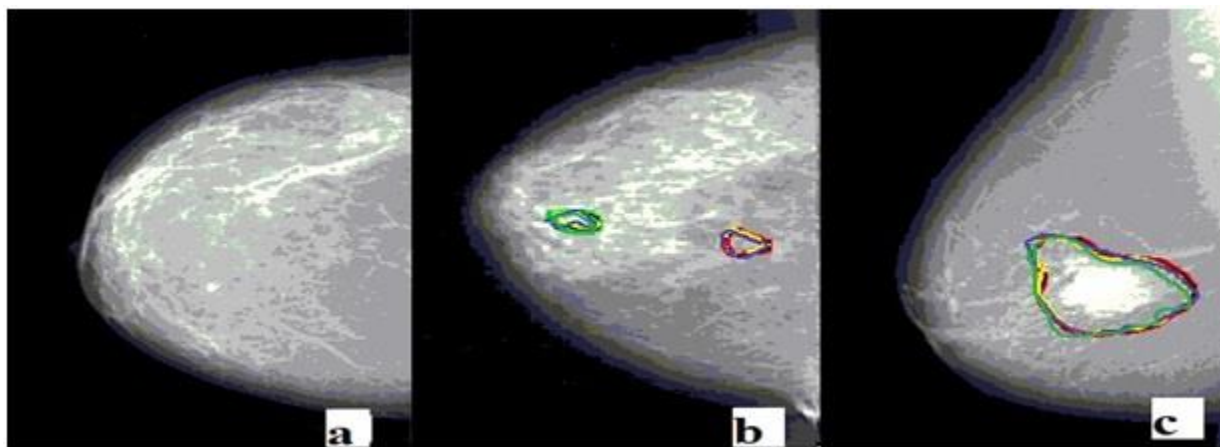


Fig 2. Mammogram (a) Normal image (b) Benign tumor (c) Malignant tumor

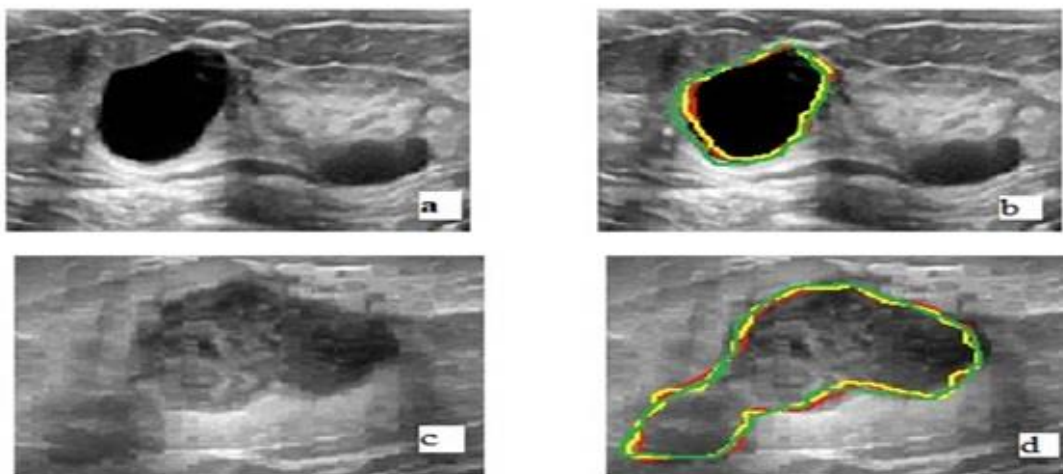


Fig. 3. Ultrasound breast Images Mammogram (a) Benign Ultrasound image (b) Benign Ultrasound image with marking (c) Malignant Ultrasound image (d) Malignant Ultrasound image with marking

The research article is organized in the following sections. The section 2 describes about the literature review, the section 3 that reveals the methodology of the research work, section 4 describes classification; section 5 describes the result and discussion, the section 6 about conclusion.

## 2. LITERATURE REVIEW

Denise Gulati, had presented fuzzy region growing segmentation [15], the growth starts from the seed pixel. The membership function of fuzzy C means, statistical measure of the region being grown. The obtained region have the information of nature of tumor either benign or malignant is in its contour, hence study of contour plays an important role for diagnose of breast cancer. However the author didn't explore the idea for the automatic classification through any classifier that is not sufficient to the radiologist for automatic assessment for the screening.

Chaitanya Varma [16] demonstrated work on alternative approach to detect breast cancer using digital image processing technique. The author proposed texture based segmentation to detect early phase tumor. It does not involve human error. The author did not attempt texture based segmentation for various types of images. Also author didn't attempt several region based

features for the diagnosis of disease. More over author did not involve automatic classifier.

Aqhsa Q[2] revealed work on detection of tumor in MRI images using artificial neural networks. In this work the author diagnosed high accuracy, lesser delay and automatic detection of brain tumor through artificial neural network. The author also presented diagnosis of brain tumor and the statistical features like mean, median, variance and correlation. The main objective of this work is to classify brain tumor cell as either benign or malignant. The author didn't work on the breast tumor images.

Lei-Zhang et. al.[17] worked on artificial intelligence algorithm for tumor detection in screening mammogram. In this work the author has combined artificial intelligence algorithms with DWT technique for identification of masses in the breast. The author worked on three different techniques such as i) fractal dimension analysis ii) Markov random chain and 3) Dog and rabbit clustering algorithm. The fractal dimension algorithms perform better to locate suspicious cancer region. The dog and rabbit adapted to initiate the segmentation at the LL() sub band for the discrete wavelet transformation decomposition of the mammogram. The author has adapted decision tree classifier for automatic classification.

Vibha Bora et. al. [10] presented mammogram segmentation using rough K-means and mass lesion classification with ANN. The author adapted rough K-means method for extraction of tumor from the breast. The pixel of the tumor objects that belong to the same regions are classified under upper approximation otherwise lower approximation. The distinction between lower and upper approximation will result in the rough boundary. The author estimated geometrical and texture properties. The textural and geometrical features are estimated from the extracted region of interest. These features will be the input to the supervised learning algorithm for ANN, whereas ANN automatically classified cancerous tumor with 95% accuracy.

Damien et. al. [17] demonstrated mammographic mass segmentation using fuzzy-C means clustering and decision tree. The author carried out work on two stages segmentation of mass anomaly and classification. In first stage, the mass anomalies had segmented with modified fuzzy-C means clustering and in the second stage; the automatic classification is achieved through decision tree. The author has classified as cancerous and noncancerous with 90%

sensitivity and 72% specificity. However this result is not appropriate to accept in the medical field.

Amara Nedra et. al. [5] focused on detection and classification of the breast abnormalities in breast mammogram via linear support vector machine (SVM). In this technique the work has been categorized into three stages , 1) optimal k value selection for k means segmentation for the breast mass 2) Robust feature based on surf interest of the estimated region of interest.3) Classification using linear support vector machine for the two benign and malignant patients.

### 3. METHODOLOGY

The section describes work flow in seven phases that as follows input, Pre-Processing, ROI extraction, determination of feature Classification and followed by Diagnosis. In the first phase, Image database has been developed using state of art technique for considering various databases such as DDSM, MIAS, Kaggle and also collected images from local hospitals. In the pre processing phase the noise has been removed using algorithm Modified Gabor [12]. In phase-2 enhancement of mammogram had been obtained with the combination of ADT and Gabor filter. The mathematical model and algorithm were presented [12].In the phase 3, the segmentation of the region of interest is extracted using the Region growing and merging and the other segmentation of ROI [13].

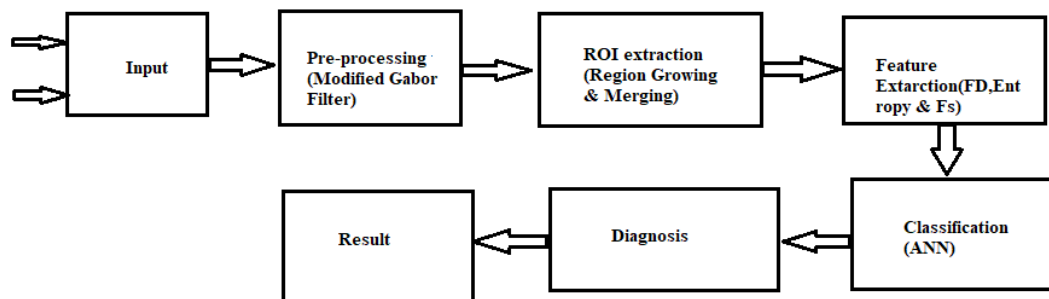


Fig.4 Data Flow diagram

Phase-IV, This is the most important phase, where various features are extracted from tumor for

the diagnosis of the breast cancer. The 16 features are as follows,

**Area:** The tumor obtained from the breast of is called area, which is in the form of number of pixels. The area is defined by the equation 1. The area of the benign and malignant tumor has been computed and tabulated in the table 1 and table 2. The actual area of the tumor from the image is to be calculated using the equation 2.

$$area = 2\pi r^2 \dots\dots\dots\text{equation 1}$$

$$actualarea = area * \frac{1}{1024} * 9.5 \dots\dots\dots\text{equation 2}$$

True area of the tumor is measured by the equation 2 and the value 0.00927734 that is the actual area occupied by the one pixel. Hence in order to obtain the actual tumor size that constant multiplied with the number of pixels obtained in the region of interest.

As per the equation 2, it has been observed that malignant tumor was of about 2 cm whereas benign tumor was 1.5 cm. Based on these can conclude that malignant tumor have larger area compared to benign tumor. Out of 1700 samples, the average value for area of 500 benign samples is 1.5 cm and 1200 malignant samples are 2 cm.

**Bounding Box :** The box /rectangle that cover the tumor/region of interest.

**Major axis Length:** It is the maximum length of the axis in the tumor. The average major axis length is 3.24 cm and malignant is 3.49 cm. The malignant tumor has higher major axis length.

**Major axis angle** is the angle between the major axis and the x-axis of the image

**Minor axis:** It is the maximum width of the axis of the tumor region defined by the equation 3. The average major axis length is 2.29 cm and malignant is 2.6 cm. It is the pixel distance between the minor-axis endpoints and is given by the relation,

$$\frac{x^2}{a^2} + \frac{y^2}{b^2} = 1 \dots\dots\dots\text{equation 3}$$

**Eccentricity:** It is defined as the ratio of the minor axis to the major axis of the tumor. The eccentric value of the malignant tumor is lesser compared to the benign tumor, because major axis of the malignant tumor is larger compared to benign tumor. Hence eccentricity would be less. The mean and SD of the experiment is obtained as 0.60 and respectively where as benign is

0.70.

$$Eccentricity = \frac{AxisLengthMinor}{AxisLengthMajor} \dots\dots\dots equation 4$$

Orientation: The angle of the tumor placed on X-Y plane is called orientation and defined by the following equation

$$\theta = \tan^{-1} \left( \frac{y_2 - y_1}{x_2 - x_1} \right) \dots\dots\dots equation 5$$

Convex area:

It is the area required for covering of the region of interest. The convex is calculated by identifying the points on the tumor region using the formula below. The coordinates (x1,y1),(x2,y2),(x3,y3),.....(xn, yn) are given ,the convex area can be calculated by

$$Area = \frac{1}{2} \begin{vmatrix} x_1 & y_1 \\ x_2 & y_2 \\ \dots & \dots \\ x_n & y_n \\ x_1 & y_1 \end{vmatrix} = \frac{1}{2}(x_1y_2 + x_2y_3 + \dots\dots\dots + x_ny_1)$$

Equi diameter: The equivalent diameter is defined as the diameter of a circle with an equal aggregate sectional area

$$d = 2 * \frac{area}{\pi} \dots\dots\dots equation 6$$

Solidity: It is the ratio of the actual area to the convex area. The benign tumor will have higher solidity as the benign tumor convex area is quite closer to the actual area of the benign. The malignant tumor will have lesser solidity as the convex area is quite larger than the actual area. It is a measure of the density of an object. The average solidity of benign 0.76 and malignant is 0.74.

$$Solidity = \frac{area}{convexarea} \dots\dots\dots equation 7$$



The Contour Based Fractal Dimension (CBFD) : This feature of the tumor is most important feature extracted from benign and malignant tumor for contour roughness analysis. The details of the derivation of CBFD had been presented [14]. The estimation of the CBFD is as follows,

$$\text{CBFD} = 1 - \log(L(\lambda)) / \log(\lambda)$$

where  $L(\lambda)$  = perimeter of the contour with step size  $\lambda$

$\lambda$  = step size

Equation can be written as follow

$$D = 1 - \text{slope}, \text{ where slope is } \log(L(\lambda)) / \log(\lambda)$$

As per the theory of fractal dimension the FD of malignant tumor is higher compared to benign as the contour is irregular. The different attribute values had been depicted in the table 1 and 2 for benign and malignant tumor.

The values of the 16 features of the tumor and its contour, benign and malignant are depicted in table 1 and table 2 respectively.

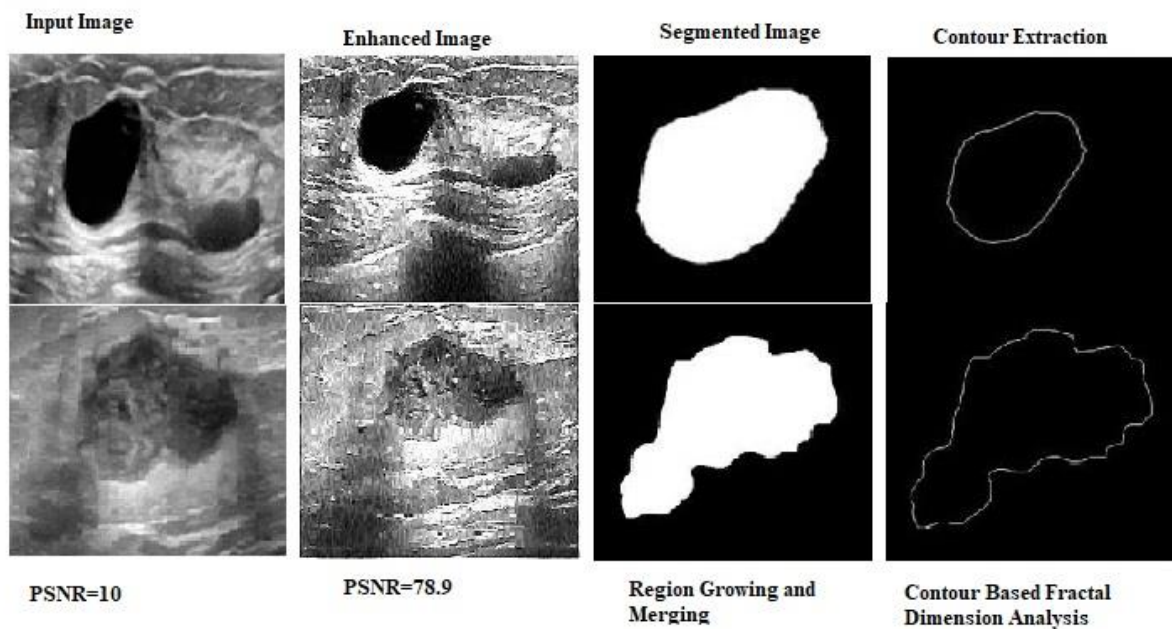


Fig.5 Extraction of Tumor and Contour in Ultrasound Images

Phase V: The dataset was constructed using state of art technique for 1700 samples, out of that 1200 are malignant and 500 are benign. The neural network is trained and tested 80:20 respectively for the classification.

Phase VI: In this classification phase the various ANN architectures are constructed and diagnosed the cancer automatically with 98% accuracy. The fourth section of the article reveals the classification in detail.

Phase VII: The result has been produced by ANN from the extracted tumor of the ultrasound and mammogram images which assist pathologist.

#### **4. RESULTS WITH CLASSIFICATION**

An Artificial Neural Network (ANN) is capable of performing simultaneous information processing in distributed structure that includes processing element called neurons. The network is to be trained through several learning algorithms categorized as unsupervised and supervised methods. Learning vector quantization (LVR) gradient descent, back propagation and radiant decent function are some of the learning algorithms. The back propagation algorithm is one of the leading methods adopted in (FF) feed forward neural networks. The knowledge earned by the experience is accumulated in the form of network weights that are used to make decision on given inputs.

In the experiment back propagation neural Network(BPNN) has three layers such as (1) input layer with 16 neurons (2) hidden layer with different set of neurons based on architecture and (3) last one is output layer with single neuron and that will diagnose the disease either benign or malignant tumor. The dataset of 1700 images was adopted containing all the two cases like malignant and benign. The results of tumor classification after training and testing the feature from tumor are depicted in the table 1 and table 2. Table 1 presents the features for the contour of the benign tumor with respect to the features like area, bounding box, major and minor axis, eccentricity, orientation, convex area, equidiameter, solidity, extent, Cbfd. Similarly the values of all the features for malignant tumor are provided in table 2. The average value of individual features demonstrates that the higher value for malignant as compared to benign samples with

respect to area, perimeter, major axis, bounding box, minor axis etc.

The different network architectures were built as shown in table 3 with 0.002 learning rate (LR) and momentum of 0.8. The salient features that are extracted from the tumor are applied for training and testing in ratio 80:20 respectively. The experiment was conducted with different epochs till the mean square error (MSE) less than  $10^{-8}$  that is shown in figure 4 and 5. With the various neural network architectures, an accuracy of 97.6 % is achieved with ten hidden layers, 97.8% for 25 hidden layers, 98.11 % accuracy for 45 and 60 hidden layers. The table 4 describes the accuracy by the ANN network for 1700 samples (98.71) and also mentioned the accuracy of rough k means for 310 samples with an accuracy of 97.3% [14].

Table 1. Different Attributes of Benign Tumor

Sl.No.	image name	Area	Bounding Box				Major axis length	Minor Axis length	Eccentricity	Orientation
1.	Benign1	48198	0.5	0.5	303	221	400.05	282.04	0.70	1.52E-13
2.	Benign2	38730	0.5	0.5	270	180	343.83	224.37	0.75	0.028071506
3.	Benign3	32574	0.5	0.5	217	170	265.75	204.90	0.63	0.032418739
4.	Benign4	41932	0.5	0.5	274	198	353.23	248.37	0.71	7.90E-14
5.	Benign5	40252	0.5	0.5	264	193	337.76	240.62	0.70	-1.04E-14
6.	Benign6	42252	0.5	0.5	272	201	350.81	251.97	0.69	2.57E-14
7.	Benign7	39244	0.5	0.5	258	190	328.52	235.98	0.69	1.01E-13
8.	Benign8	46682	0.5	0.5	293	217	384.53	275.49	0.69	9.09E-14
9.	Benign9	45862	0.5	0.5	293	212	383.62	269.00	0.71	-1.21E-13
10.	Benign10	46118	0.5	0.5	275	223	358.69	280.59	0.62	4.59E-14
11.	<b>Averagevalb</b>	<b>41703.6</b>	<b>0.5</b>	<b>0.5</b>	<b>271.6</b>	<b>197.73</b>	<b>349.78</b>	<b>247.73</b>	<b>0.70</b>	<b>0.006247139</b>

Convex area	equi diameter	solidity	Extent	perimeter	FD(GM)	FD(AM)	Target
66963	247.72	0.71	0.71	1022.75	1.45	1.49	1
48600	222.06	0.79	0.79	877.71	1.55	1.58	1
36890	203.65	0.88	0.88	754.23	1.48	1.52	1
54252	231.06	0.77	0.77	920.83	1.61	1.65	1
50952	226.38	0.78	0.78	891.43	1.61	1.62	1
54672	231.94	0.77	0.77	922.79	1.72	1.73	1
49020	223.53	0.80	0.80	873.79	1.46	1.48	1
63581	243.79	0.73	0.73	995.31	2.04	2.24	1
62116	241.64	0.73	0.73	985.51	1.43	1.48	1
61325	242.32	0.75	0.75	971.79	1.68	1.68	1
66963	247.72	0.71	0.71	1022.75	1.45	1.49	1

Table 2. Different attributes of Malignant Tumor

Sl.No.	Image name	Area	Bounding Box				Major axis length	Minor Axis length	Eccentricity
1.	Malignant 2	53074	0.5	0.5	333	235	447.13	304.35	0.73
2.	Malignant 3	54473	0.5	0.5	313	253	420.28	324.67	0.63
3.	Malignant 5	34548	0.5	0.5	234	173	290.61	210.90	0.68
4.	Malignant 6	50580	0.5	0.5	285	244	376.42	308.65	0.57
5.	Malignant 7	43032	0.5	0.5	279	200	359.77	250.97	0.71
6.	Malignant 8	39483	0.5	0.5	273	183	348.72	228.61	0.75
7.	Malignant 9	40675	0.5	0.5	260	197	332.23	244.98	0.67
8.	Malignant 10	45079	0.5	0.5	269	219	348.79	274.31	0.61
9.	Malignant 11	48478	0.5	0.5	291	229	383.60	290.70	0.65
10.	Malignant 12	54454	0.5	0.5	309	256	415.02	328.20	0.61
	<b>Averageval</b>	<b>43286.45</b>	<b>0.5</b>	<b>0.5</b>	<b>287.18</b>	<b>222</b>	<b>376.62</b>	<b>281.00</b>	<b>0.66</b>

## NOVEL FEATURE SET FOR AUTOMATIC ASSESSMENT AND CLASSIFICATION

Orientation	Convex area	equi diameter	Solidity	extent	perimeter	FD (GM)	FD (AM)	Target
4.53E-14	78255	259.95	0.67	0.67	1108.99	1.92	2.29	2
0.055181565	79189	263.35	0.68	0.68	1105.07	1.69	1.79	2
0.03115225	40482	209.73	0.85	0.85	793.43	1.58	1.68	2
0.066140777	69540	253.77	0.72	0.72	1032.55	2.31	2.49	2
0.037154487	55800	234.07	0.77	0.77	934.55	1.38	1.41	2
0.028847869	49959	224.21	0.79	0.79	889.47	1.55	1.58	2
0.038627236	51220	227.57	0.79	0.79	891.43	1.32	1.35	2
0.051484113	58911	239.57	0.76	0.76	952.19	1.77	1.79	2
-2.05E-13	66639	248.44	0.72	0.72	1014.91	1.47	1.51	2
-1.09E-13	79104	263.31	0.68	0.68	1103.11	2.24	2.52	2
<b>0.033069987</b>	<b>64389.81</b>	<b>244.30</b>	<b>0.74</b>	<b>0.74</b>	<b>993.71</b>	<b>1.72</b>	<b>1.84</b>	

The performance of the various architectures

Table 3. Performance Analysis on Various Architecture

Neural Network Architecture (I-(H)-O)	TP	TN	FP	FN	Step size , epoch	Accuracy
18-60-1	98.41	97.41	1.58	2.6	0.02,10,000	98.11
18-45-1	98.41	97.41	1.58	2.6	0.02,10,000	98.11
18-25-1	97.2	1.91	1.91	2.8	0.02,10,000	97.8
18-10-1	98	96.8	2	3.2	0.02,10,000	97.6

Table 4. Accuracy of samples tested

Total No. of Cases tested	No. of Malignant samples	No. of Normal Samples	No. of samples predicted incorrect malignant	No. of samples predicted incorrect normal	Accuracy
1700	1200	500	19	13	98.11
310	75	231	2	9	97.3

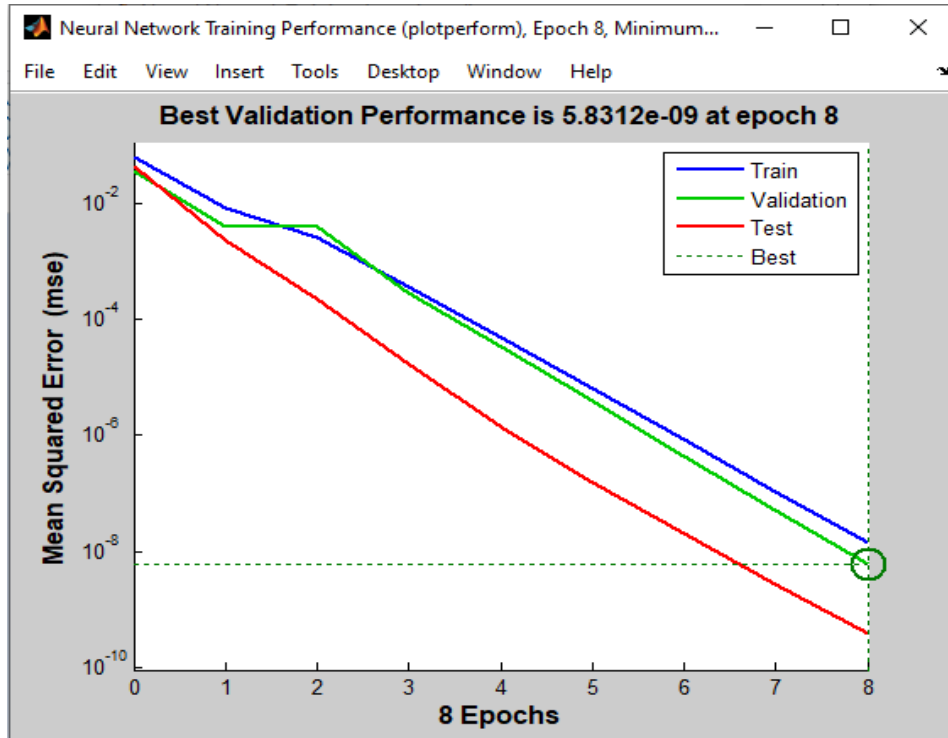


Fig. 6 Performance

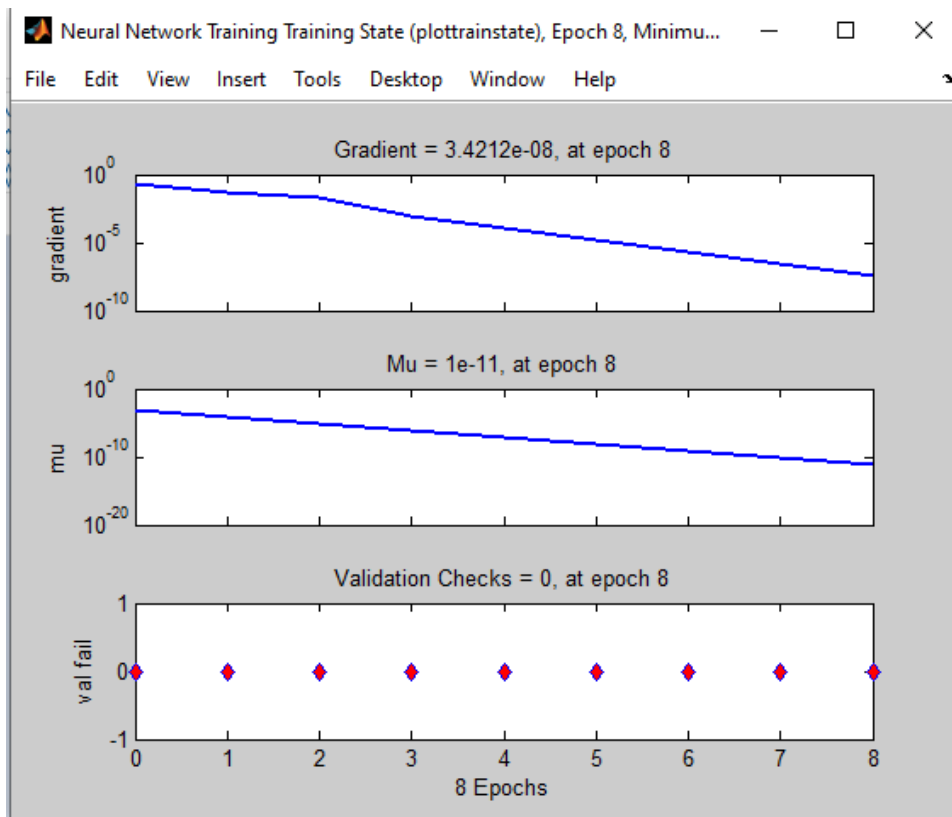


Fig. 7 Regression

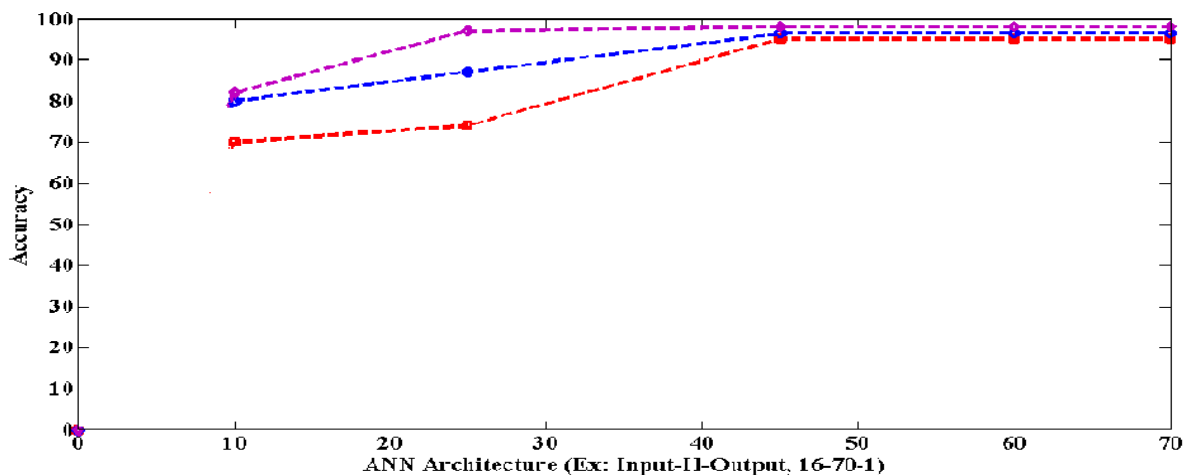


Fig. 8 ANN Graph

The figure 6 shows the graph plotted different network architectures against accuracy. From the graph it can be inferred that better accuracy could be achieved with the increase in the number of hidden neurons and performance was saturated for 45 and above.

The Dataset of the breast tumor, X-ray mammogram used in this novel research work was downloaded from DDSM online database and some mammograms from local hospitals. All these are considered for experimental work. That database contains 1700 images of several patients. In that, 1200 number of images are malignant and 500 are benign tumor. All the dataset images detection result of the patients was confirmed through biopsy test.

The research work was experimented on MATLAB package [2013R] software for the classification using back propagation neural network. It can be inferred that CBFD is the best features in terms of test and easy way to classify the tumor on x-ray and ultrasound images.

Cancer tumors are the one that proven dangerous to the patient and hence required to take immediate attention. In order to evaluate the performance of the experiment sensitivity and specificity of diagnosis had been considered these two are statistical metrics terms which focus an importance of features related to find the presence and absence of the cancer tumor

## **5. CONCLUSION**

In this work we have addressed the problem automatic classification of malignant and benign tumor using back propagation artificial neural network. Prior to this the input image has been enhanced by using modified Gabor filter [12] and that makes better visibility of the tumor in the ultrasound and mammogram. Then the region growing and merging algorithm is applied for the extraction of tumor region in the mammogram. The region growing and merging technique is the most accurate method for the segmentation of the contour of the tumor. From the tumor, the novel features like Cbfd, tumor area, eccentricity etc. are extracted. In the existing work the tumor region FD had been analyzed using box counting technique that was not so accurate compared to contour based fractal dimension because this algorithm analyses purely on boundary of the tumor with various scale size and that produces excellent result[14]. With these feature set the automatic classification had been done using three layer back propagation ANN for 1700 samples, And arrived 98.11% accuracy which is depicted in the table 3 in the result with classification section and error rate will be minimum. It can be inferred that Cbfd feature is the best among other features for the malignant tumor classification from the benign set. The Radiologist can consider this as a one of the important feature to diagnose the breast cancer detection. In future the algorithms like decision tree, random forest, and deep learning approach can be applied for higher accuracy and also faster classification and detection of tumor.

## **ACKNOWLEDGMENT**

We thank for the Visvesvaraya Technological University Belagavi and the SDM Hospital, Dhrawad, Karnataka, India which provided the data samples for the research.

## **CONFLICT OF INTERESTS**

The authors declare that there is no conflict of interests.



**REFERENCES**

- [1] L. Zhen, A.K. Chan, An artificial intelligent algorithm for tumor detection in screening mammogram, *IEEE Trans. Med. Imaging.* 20 (2001), 559–567.
- [2] A.Q. Syed, K. Narayanan, Detection of tumor in MRI images using artificial neural networks, *Int. J. Adv. Res. Electric. Electron. Instrument. Eng.* 3 (9), 11749-11754.
- [3] C.A. Ancy, L.S. Nair, An efficient CAD for detection of tumour in mammograms using SVM, in: 2017 International Conference on Communication and Signal Processing (ICCSP), IEEE, CHENNAI, India, 2017: pp. 1431–1435.
- [4] M. Mohamed Fathima, D. Manimegalai, S. Thaiyalnayaki, Automatic detection of tumor subtype in mammograms based On GLCM and DWT features using SVM, in: 2013 International Conference on Information Communication and Embedded Systems (ICICES), IEEE, Chennai, 2013: pp. 809–813.
- [5] A. Nedra, M. Shoab, S. Gattoufi, Detection and classification of the breast abnormalities in Digital Mammograms via Linear Support Vector Machine, in: 2018 IEEE 4th Middle East Conference on Biomedical Engineering (MECBME), IEEE, Tunis, 2018: pp. 141–146.
- [6] A. Helwan, R.H. Abiyev, ISIBC: An intelligent system for identification of breast cancer, in: 2015 International Conference on Advances in Biomedical Engineering (ICABME), IEEE, Beirut, Lebanon, 2015: pp. 17–20.
- [7] B. Pushpa, F. Louies, Detection and classification of brain tumor using machine learning approaches. *Int. J. Res. Pharm. Sci.* 10 (2019), 2153-2162.
- [8] D. Sankar, T. Thomas, Breast cancer detection using entropy based fractal modeling of mammograms, *Int. J. Recent Trends Eng.* 1 (3) (2009), 171-175.
- [9] S.S. Sinare, P.S. Vikhe, Fuzzy C-means clustering Algorithm for breast cancer detection, *Int. J. Adv. Innov. Res.* 1 (2012), 307-310.
- [10] V.B. Bora, A.G. Kothari, A.G. Keskar, Mammogram Segmentation Using Rough k-Means and Mass Lesion Classification with Artificial Neural Network, in: A.E. Hassanien, A.-B.M. Salem, R. Ramadan, T. Kim (Eds.), *Advanced Machine Learning Technologies and Applications*, Springer Berlin Heidelberg, Berlin, Heidelberg, 2012: pp. 60–69.
- [11] S.V. Shwetha, L. Dharmanna, Literature Survey on Early Detection of Malignant Tumor Through Computerized Technique, *J. Comput. Theor. Nanosci.* 17(9-10) (2020), 3873-3877.
- [12] S.V. Shwetha, L. Dharmanna, S. Basavaraj Anami, Design and methodology of algorithm for the enhancement of breast tumor images, *IOP Conf. Ser.: Mater. Sci. Eng.* 994 (2020), 012020.
- [13] A. Rahmatika, A. Handayani, A.W. Setiawan, Automated Segmentation of Breast Tissue and Pectoral Muscle in Digital Mammography, in: 2019 International Conference of Artificial Intelligence and Information Technology (ICAIIIT), IEEE, Yogyakarta, Indonesia, 2019: pp. 397–401.

- [14] S.V. Shwetha, L. Dharmanna, Automatic Detection And Classification Of Malignant Tumor In Mammograms Image Using Image Feature Fractal Dimension, *Int. J. Sci. Technol. Res.* 9 (2020), 796-802.
- [15] D. Guliato, R.M. Rangayyan, W.A. Carnielli, J.A. Zuffo, J.E.L. Desautels, Segmentation of breast tumors in mammograms by fuzzy region growing, in: *Proceedings of the 20th Annual International Conference of the IEEE Engineering in Medicine and Biology Society. Vol.20 Biomedical Engineering Towards the Year 2000 and Beyond* (Cat. No.98CH36286), IEEE, Hong Kong, China, 1998: pp. 1002–1005.
- [16] C. Varma, O. Sawant, An Alternative Approach to Detect Breast Cancer Using Digital Image Processing Techniques, in: *2018 International Conference on Communication and Signal Processing (ICCSP)*, IEEE, Chennai, 2018: pp. 0134–0137.
- [17] X. Zhang, Y. Zhang, E.Y. Han, N. Jacobs, Q. Han, X. Wang, J. Liu, Classification of Whole Mammogram and Tomosynthesis Images Using Deep Convolutional Neural Networks, *IEEE Trans. Nanobiosci.* 17 (2018), 237–242.
- [18] D. Valdés-Santiago, R. Quintana-Martínez, Á. León-Mecías, M.L. Bager Díaz-Romañach, Mammographic Mass Segmentation Using Fuzzy C-means and Decision Trees, in: F.J. Perales, J. Kittler (Eds.), *Articulated Motion and Deformable Objects*, Springer International Publishing, Cham, 2018: pp. 1–10.