



Available online at <http://scik.org>

J. Math. Comput. Sci. 11 (2021), No. 4, 4284-4300

<https://doi.org/10.28919/jmcs/5788>

ISSN: 1927-5307

A NOVEL APPROACH TO GLAUCOMA SCREENING USING OPTIC NERVE HEAD THROUGH IMAGE FUSION AND FRACTAL GEOMETRY

S. CHANDRAPPA^{1,*}, L. DHARMANNA², BASAVARAJ ANAMI³, C. NANDINI⁴, MOHAMMED RAFI⁵

¹Department of ISE, GSSS Institute of Engineering & Technology for Women, Mysuru-570016, India

²Dept. of ISE, SDMIT, Ujire-574240, India

³The Principal, K.L.E Institute of Technology, Hubli-580030, India

⁴Department of CSE, Dayananda Sagar Academy of Technology & Management, Bangalore-560082, India

⁵Department of CSE, University BDT College of Engineering, Davangere-577004, India

Copyright © 2021 the author(s). This is an open access article distributed under the Creative Commons Attribution License, which permits unrestricted use, distribution, and reproduction in any medium, provided the original work is properly cited.

Abstract: The Glaucoma is a typical eye issue that causes vision loss. It leads to visual impairment if it is untreated on time. Normally, vision loss is slow and not perceptible. Regular and systematic eye assessments are suggested for persons from middle age to prevent further vision loss. The proposed system introduced a new technique in the field of ophthalmology to diagnose glaucoma in an effective way using Image Fusion and Fractal Geometry techniques. The optic cup and disc are extracted from fundus images using K-means and Thresholding techniques. Optic cups generated by the techniques are combined to obtain the better cup region using the image Fusion Technique to improve the glaucoma screening process. The same process is applied on optic discs to obtain the fused disc area. The Box counting fractal dimension estimation technique from Fractal Geometry is applied on fused areas to classify the image as either healthy or glaucoma. Results of these two techniques are evaluated on a publically

*Corresponding author

E-mail address: chandru21@gmail.com

Received March 31, 2021

available HRF dataset and obtained the accuracy of 97%.

Keywords: glaucoma; image; fractal dimension; image fusion; optic nerve head.

2010 AMS Subject Classification: 93A30, 28A80.

1. INTRODUCTION

Billions of people continue to open increased risk of visual deficiency or huge visual disability. It reduces the quality of human life if the condition is undiscovered, left untreated and not diagnosed on time. Glaucoma is the one cause for visual deficiency. Hence, early discovery of glaucoma is important to strengthen the assistances of treatment and it remains a challenge when it is undiagnosed in the community. According to survey, it is shown that expenses of treating glaucoma in many of developed countries increase as severity of glaucoma [1]. If glaucoma patients are not correctly identified and treated at the prior stages leads to reduction in reserve funds and causes burdens on healthcare facilities. In current era, medical field equipped with advanced instruments but require new approaches to diagnose diseases in its initial-phase. There are different clinical parameters and approaches to detect glaucoma in the early stage [2-6]. Following sections describes the different methods proposed by various authors to detect glaucoma.

Ajesh et al., [7] developed a methodology for finding glaucoma condition at the initial stage by examination of retinal features extracted from fundus image using imaging process techniques. Authors presented an improved machine learning algorithm to discover the disease. A discrete wavelet transform (DWT) is used for classifying the diseases. Proposed methodology provided the better results and achieved 95 percentage of accuracy. J. Carrillo et al., [8] illustrated the basic concepts of glaucoma and different screening techniques. This work presented the computational tool to extract disc and cup areas from the fundus images using thresholding technique. The proposed method was tested on Center of Prevention and Attention of Glaucoma in Bucaramanga, Colombia dataset and obtained the accuracy of 88.5%.

Guangzhou An et al., [9] developed an convolutional neural network (CNN) and random forest (RF) algorithms based technique to diagnose the open-angle glaucoma. Work is focused on

retinal nerve fiber layer thickness; optic disc and macular ganglion cell complex (GCC) present in Optical coherence tomography and fundus data. Proposed method generated deviation and thickness maps using segmentation approaches. It is evaluated on 357 images and obtained an AUC of 0.963. In [10], authors presented a new tool for detection of glaucoma using fundus images. They extracted local configuration pattern (LCP) based features and texton from the images to analyze the glaucoma status. Texton are generated by applying adaptive histogram equalization and convolution operations on images. The proposed method achieved the accuracy of 95.8%. Simonthomas, S et al., [11] presented new computerized approach to glaucoma diagnosis. The authors extracted the Gray Level Co-occurrence Matrix (GLCM) and Haralick based texture features to diagnose the glaucoma disease. The Image pre-processing is performed to eliminate the noises. Later, Noise free image is used to extract the GLCM and thirteen Haralick texture features. Finally, all these features are feed to k-nearest neighbors classification technique and achieved the 97% accuracy.

Abhishek Pal et al., [12] presented auto encoding system called G-EYENET to identify the glaucoma. The modified u-net CNN is used to extract Region of Interest consisting of Optic Disc from fundus images. Authors considered RIM ONE v3, Drishti-GS, HRF databases for training the system and DRIONS-DB for testing purpose. The G-EYENET achieved the AUC of 0.923. Juan J et al., [13] developed a transfer learning approach to glaucoma detection. Optic disc is segmented by morphological operations then VGG-19 net is used for transfer learning. The approach achieved the AUC of 0.94. Alan Carlos de Moura Lima et al., [14] proposed a CNN based RNN architecture version 50 to study process of glaucoma in patients. The approach achieved the accuracy of 90%. Annan Li et al., [15] presented an approach to glaucoma detection using CNN. The deformable shape model is used to segment the optic disc from image. From extracted optic disc, features are calculated and combined to form the feature vector which consisting the 19,456 features. Obtained features are feed to SVM classifier and obtained an AUC of 0.838. Yidong Chai et al., [16] developed a method for glaucoma analysis using MBNN method. The method calculated CDR, RNFLD to diagnose the disease. The Accuracy achieved is 91.5 %.

2. METHODOLOGY

The steps involved in the proposed method are illustrated in Figure 1. Color image captured from the fundus camera is input to proposed method. It works on two methods 1) simple thresholding and 2) K-means clustering techniques. In simple thresholding, The RGB channels are separated from the color image. Green channel image is selected for further processing because it has high density vascular architecture at optic nerve head region. The region of interest (RoI) considered for glaucoma detection is optic nerve head (ONH) area which is extracted by simple thresholding method. Reason for this RoI selection is ONH has more damaged area in glaucoma condition compared to healthy. Using RoI, the Cup and disc areas are extracted by considering the threshold values 150 and 130 respectively. On other side, K-means clustering is applied on RoI image to get another set of cup and disc areas by considering $k=4$. The boundaries of cups and discs portions are marked separately to calculate the Fractal Dimension (FD) values. To improve the efficiency of glaucoma detection, the results of both the methods are fused using image fusion technique. Cup area of thresholding method fused with cup area of K-means method and same operation is applied on discs to get better disc areas. Main aim of image fusion is to obtain accurate cup and disc areas, which is achieved by combining the results of two feasible methods (thresholding and K-means). Finally, FD values are calculated for thresholding method outputs, K-means method outputs and fused areas. A simple if else based classifier is used to classify the image as glaucoma or healthy. The methods used in the proposed approach are explained in the following sections

A. Simple thresholding

Simple thresholding is a standard, effective and commonly used segmentation method. It is used for partitioning image or extraction of object areas from image. This technique converts the grayscale image into binary image to make the image analysis easier. A threshold is a predefined value which separates the complete area into two regions. One is below the threshold and another is above the threshold. Each pixel value in the grayscale image is compared with the predefined threshold value. If the pixel value is larger than the threshold value then corresponding position in the output image is set 0. Else, position in the output image is set 255 (maximum value). Threshold value is set to 150 to obtain cup area and 130 to obtain disc area

Algorithm: Simple thresholding

Input: Grayscale image (f), Threshold (T)

Output: Segmented binary Image (s)

Step1: for each pixel $f(x,y)$ in f

Step 2: If $f(x, y) > T$ then $s(x, y) = 0$

Step3: else $s(x, y) = 255$

B. K-means clustering

K-means clustering is a segmentation algorithm. It divides the image into different clusters, each cluster consisting pixels similar to other pixels in the same cluster and different than those in other clusters. Algorithm divides the image into K clusters, among these clusters one of the clusters represents the disc and one more represents the cup. By experimental observation, value of K selected is 4. The cluster 3 represents the disc area and cluster 4 represents the cup area.

Working principle of K-means algorithm is as follow

Algorithm: K-means

Input: color image (I), $K=4$

Output: Segmented binary Images(c_1, c_2, c_3, c_4)

Step1: Randomly select K pixels as initial clusters

Step 2: Allocate each pixel in the image to the closest centroid

Step3: Calculate the center of the clusters

Step 4: For every clusters, Find the distance between pixels and centers using Euclidean distance.

Step 5: Based on calculated distance reassign the pixels to nearest clusters

Step 6: Again find the center of new clusters

Step 7: Repeat the steps 4,5 and 6 until pixels don't change the cluster

C. FD Estimation

Fractal dimensions are used to define the dimension of asymmetrical, irregular objects. The best widespread technique to estimate the irregularities in objects is Counting Method [17]. It divides the entire image with fixed-grid of square boxes of the same size r . it cover the objects in the binary image with square boxes and counts the number of boxes, $N(r)$. The $N(r)$ of boxes

required to cover the optic cup/disc depends on r :

$$N(r) \sim r^{-D} \quad (1)$$

Hence, the box counting method calculate dimension of fractal structure (cup/disc) considering the number of boxes occupied the fractal structure, $N(r)$, for different values of box size r . values for r considered in this work are 4, 8, 16 and 32. Graph is plot on the log of $N(r)$ versus the log of r and finally, the box-counting fractal dimension (FD) is calculated from the Richardson's plot best fitting curve slope as shown in (2). The optic disc and cup areas are irregular in shapes. Therefore FD takes fraction value.

$$-D = \lim_{r \rightarrow 0} \log N(r) / \log r \quad (2)$$

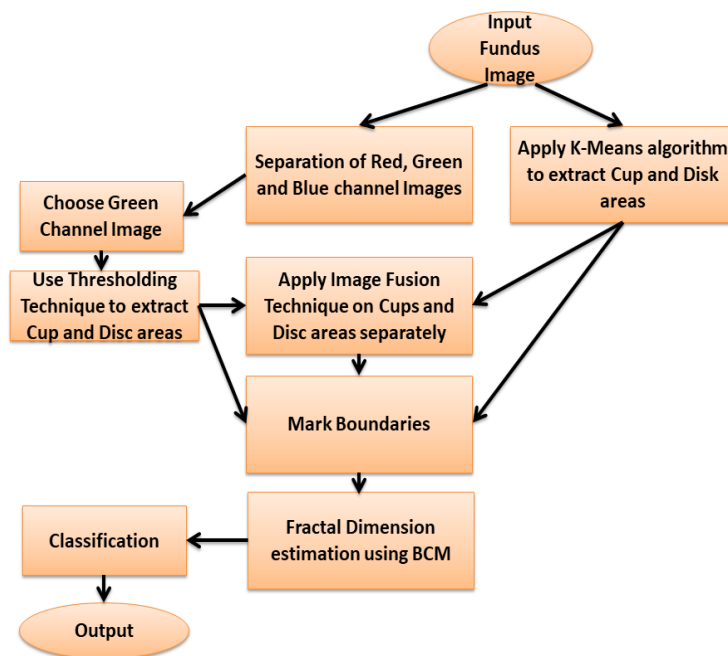


Fig. 1 Block diagram of proposed work

3. RESULTS

The proposed approach is evaluated on publically available High-Resolution Fundus (HRF) Database found at webpage [18]. It has 45 retinal fundus images, out of which 15 healthy images and 30 are glaucoma affected. In this work, one ophthalmologist marked optic disc and cup areas are considered for accuracy calculation. Dice method [19] is not a sufficient method to measure the performance of proposed method because area marked by the ophthalmologist not accurately correlating with area extracted by the proposed method due to high level of pixels variations in

glaucoma images. Hence, both dice coefficient and accuracy estimation [20] methods are used for performance measurements.

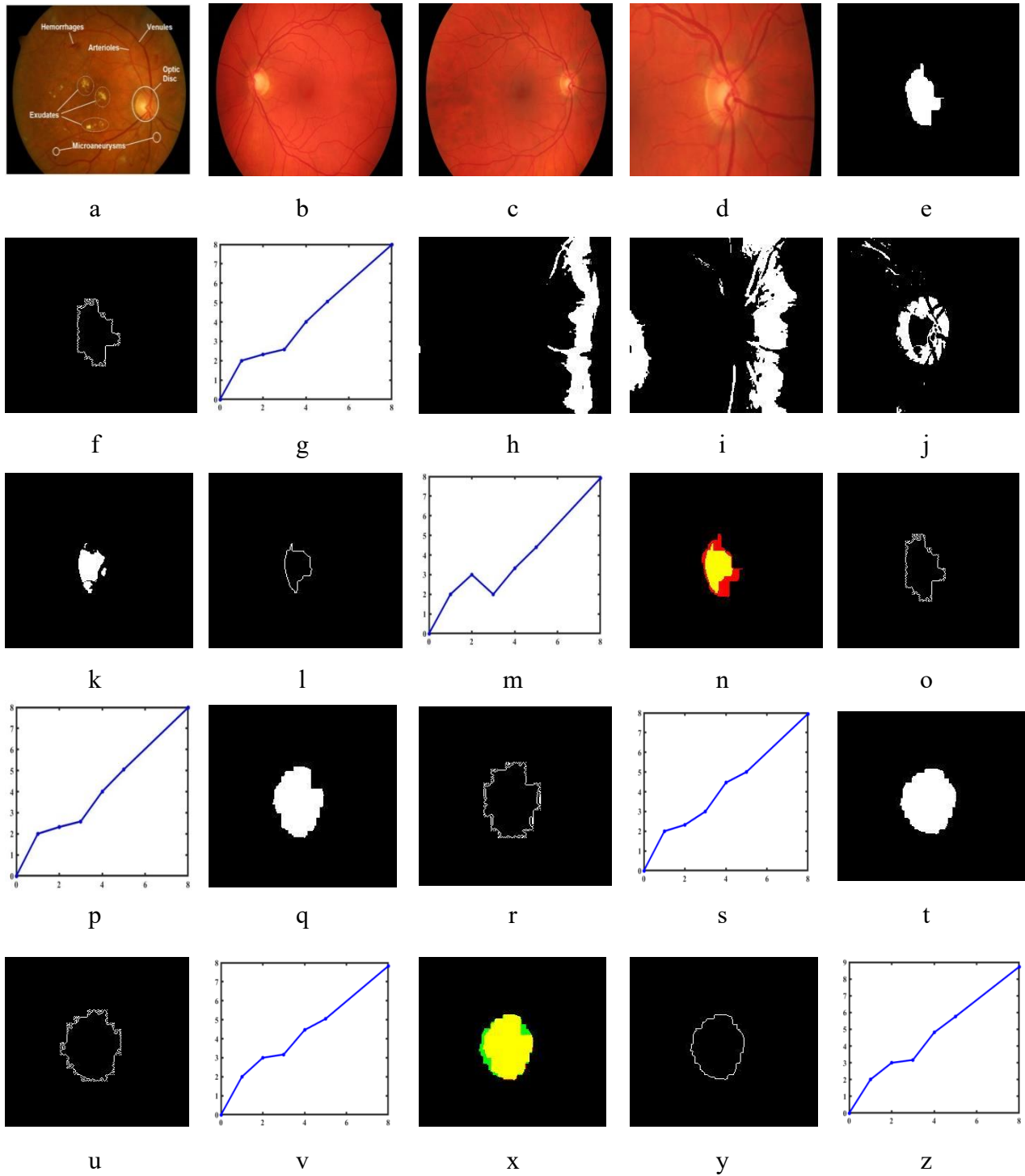


Fig. 2 Processing of Glaucoma Image

Steps involved in the glaucoma image processing are illustrated in the figure 2. Figure 2 a) illustrates the structure of retinal fundus image [21]. b) Shows healthy retinal image. c) Represents the glaucoma image. d) Illustrate the RoI extracted from the fundus image using simple thresholding method with a threshold value of 170. e) Illustrates the optic cup extracted from optic nerve head using simple thresholding method with a threshold value of 150 after obtaining the RoI of size 252X252. f) Represents boundaries extracted using morphological operations. g) illustrates the FD calculation using Box counting method, the x-axis represents the $\log(r)$ value (the number of boxes in the vertical grid) and y-axis represents the $\log N(r)$ value (number of boxes covered the cup boundaries) and obtained FD value using (2) is 1.0438. Figure h) i) j) and k) represents the clusters generated by the K-means method. Figure l) represents boundaries extracted from the image (k). Figure m) illustrates the FD calculation from slope of the line same as figure (g) and obtained FD value of 1.1895. Figure n) illustrates the cup area of thresholding method fused with cup area of K-means method using image fusion function. Figure o) represents the boundaries of image (n). Figure p) shows the FD calculation for image (o) and obtained FD value is 1.1895. Figures from q) to z) represent the operations related to disc area. Figures q) r) s) represents same operations of figure e, f and g respectively but threshold value considered here is 130 to extract optic disc. Figure t) illustrates the disc area generated from cluster 3 by applying the morphological operations. Figure u) v) x) y) and z) represents same operations of figures l, m, n, o and p respectively. The FD values obtained are 1.3483, 1.4061 and 1.5607 from thresholding, K-means and image fusion approaches.

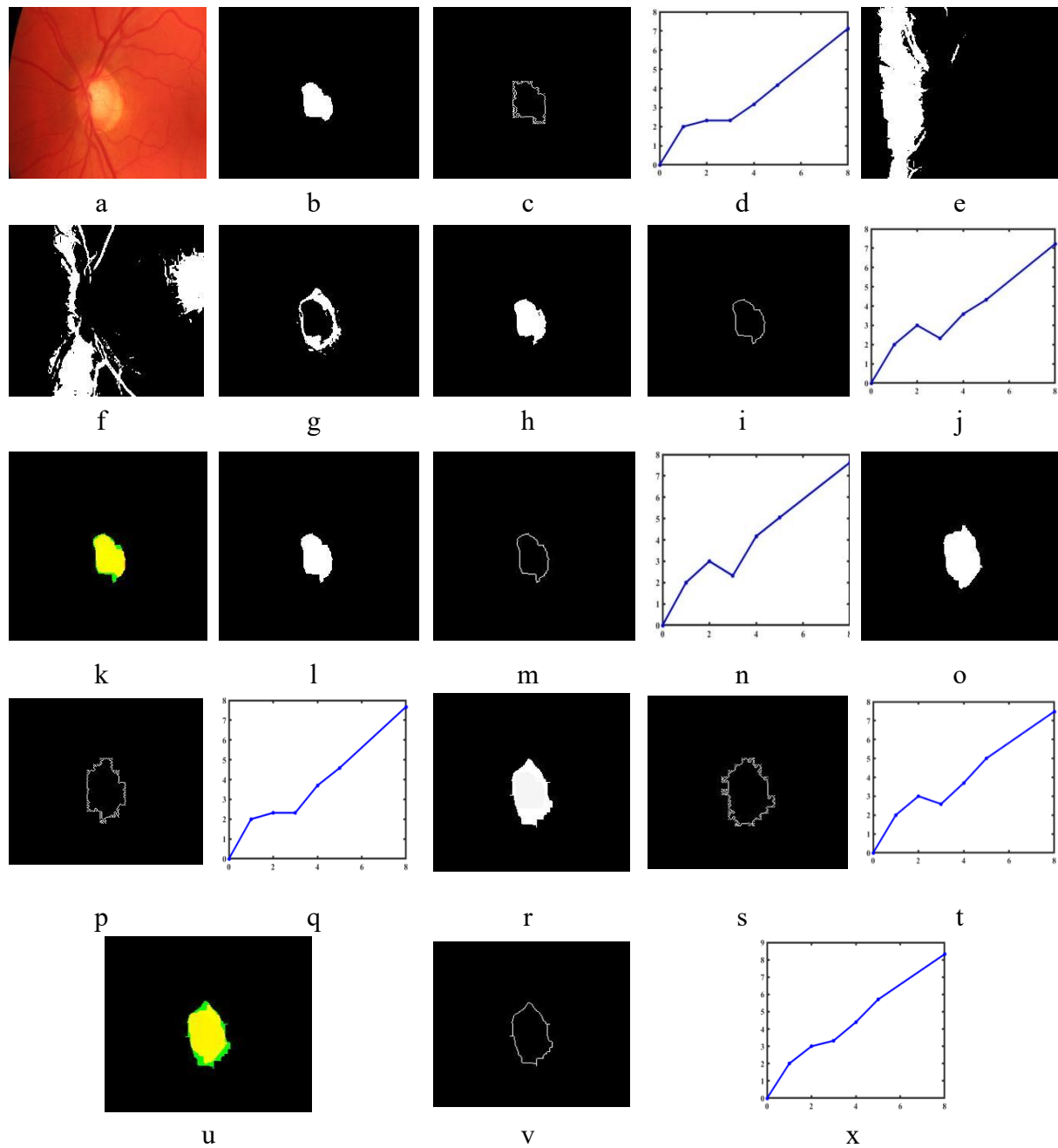


Fig. 3 Healthy Image processing

Steps involved in processing of healthy image are illustrated in the figure 3. Figure 3 a) is similar to 2 d) on healthy image. Figure 3 b), c) and d) represents the similar operations of 2 e), f) and g) respectively and obtained an FD value using (2) is 0.8733. Figure 3 e) f) g) and h) represents the clusters generated by the K-means method. Figure i) illustrates the boundaries extracted from the

image (h). Figure j) illustrates the FD calculation from slope of the line and obtained FD value of 0.8393. Figure k) illustrates the fused cup area using image fusion technique. Figure l) represents the boundaries of image (k). Figure m) shows the FD calculation for image (l) and obtained FD is 0.9136. Figures from o) to x) represent the operations related to disc area extraction and FD calculations on healthy image. Figures o) p) and q) represents same operations of figure b, c and d respectively but threshold value considered here is 130 to extract optic disc. Figure r) illustrates the disc area obtained from cluster 3 by applying the morphological operations. Figure s) t) u) v) and x) represents same operations of figures i, j, k, m and n respectively. The FD values obtained are 1.1558, 1.092, and 1.1615 on tresholding, k-means and image fusion generated disc areas respectively.




Fig. 4 Glaucoma Image similarity index calculation

Figure 4 illustrates the similarity regions of cup and disc areas obtained by comparing the ophthalmology marked cup and disc areas with thresholding, K-means and image fusion approaches generated results. Figure 4 a) is the ophthalmologist annotated cup area (ground truth area). Figure b) is the area extracted from ophthalmology annotation. c) Illustrate the Similarity index on cup area extracted from the thresholding method with ground truth area. The obtained index value is 0.83. d) Illustrate the Similarity index on cup area extracted from K-means method with ground truth area. The obtained index value is 0.73. e) Illustrate the Similarity index on image

fusion method generated cup area with ground truth area. The obtained index value is 0.83. Representation of figures f, g h I and j are same as a, b, c,d and e on optic disc respectively and obtained similarity index values are 0.92, 0.90 and 0.92 respectively. Average index values obtained on thresholding, k-means and image fusion are 0.84, 0.72 and 0.86 on cup and 0.92, 0.88 and 0.94 on disc respectively.

Description of Figure 5 is similar to figure 4 but it's on healthy image. Dice index values for figures c, d and e are 0.88, 0.87 and 0.88 and for figures h, i and f are 0.86, 0.88 and 0.88. Average index values obtained on thresholding, k-means and image fusion are 0.88, 0.84 and 0.90 on cup and 0.94, 0.90 and 0.96 on disc respectively.




Fig. 5 Healthy Image similarity index calculation

Table 1. Confusion matrix on HRF dataset

		Truth		
		Glaucoma	Healthy	Total
Test Results	Positive	30	1	31
	Negative	0	14	14
Accuracy=0.98 Sensitivity=1.0		30	15	45

The accuracy of proposed method is calculated from the confusion matrix. True positive (TP) represents the number of cases correctly identified as glaucoma. False positive (FP) represents the number of cases incorrectly identified as glaucoma. True negative (TN) represents the number of cases correctly identified as healthy. False negative (FN) represents the number of cases incorrectly identified as healthy. The accuracy of a method is represents the ability of a method to differentiate glaucoma and healthy cases in the images correctly.

Mathematically, it is represented as:

$$\text{Accuracy} = \frac{TP+TN}{TP+TN+FP+FN} \quad (3)$$

Sensitivity represents the ability of method to identify true positives correctly. Mathematically, it is represented as:

Table 2 Accuracy of the proposed framework and existing approaches.

Authors	Method	Accuracy
Ajesh et al.,[7]	DWT	95%
Carrillo et al.,[8]	Thresholding	88.5%.
Guangzhou An et al.,[9]	CNN and RF	AUC of 0.963
U Rajendra Acharya et al., [10]	Texton and LCP	95.8%.
Simonthomas, S et al.,[11]	GLCM and Haralick based texture features	97%
Abhishek Pal et al., [12]	G-EYENET	AUC of 0.923
Juan J. et al., [13]	Transfer learning approach	AUC of 0.94
Alan Carlos et al., [14]	CNN	90%
Annan Li et al.,[15]	Texture features and SVM classifier	AUC of 0.838.
Yidong Chai et al., [16]	MBNN method	91.5 %.
Proposed Method	Image Fusion and FD	97%

$$\text{Sensitivity} = \frac{TP}{TP+TN} \quad (4)$$

Table 1 illustrates the confusion matrix on HRF dataset. Proposed method detected 14 images as healthy out of 15 healthy images and 1 as glaucoma. On the other side, method detected the 30 glaucoma images as glaucoma. Therefore accuracy achieved is 97%. Table 2 illustrates the comparison of accuracy of method with existing approaches and obtained the better accuracy compared to other approaches. Figure 6 illustrates the Calculated FD values using thresholding, K-means and image fusion techniques on HRF dataset. Threshold FD value for healthy cup is below 1.035 and above 1.035 is considered as glaucoma. Threshold FD value for healthy disc is below 1.32 and above 1.32 is considered as glaucoma. Figure 6 illustrates the FD values calculated on results of thresholding, K-means and image fusion techniques. Graph a) illustrates the FD values of Cup areas. Graph b) illustrates the FD values of Disc areas. Here, G represents the glaucoma image and H represents the healthy image. Figure 7 shows the average FD values on results of three methods.

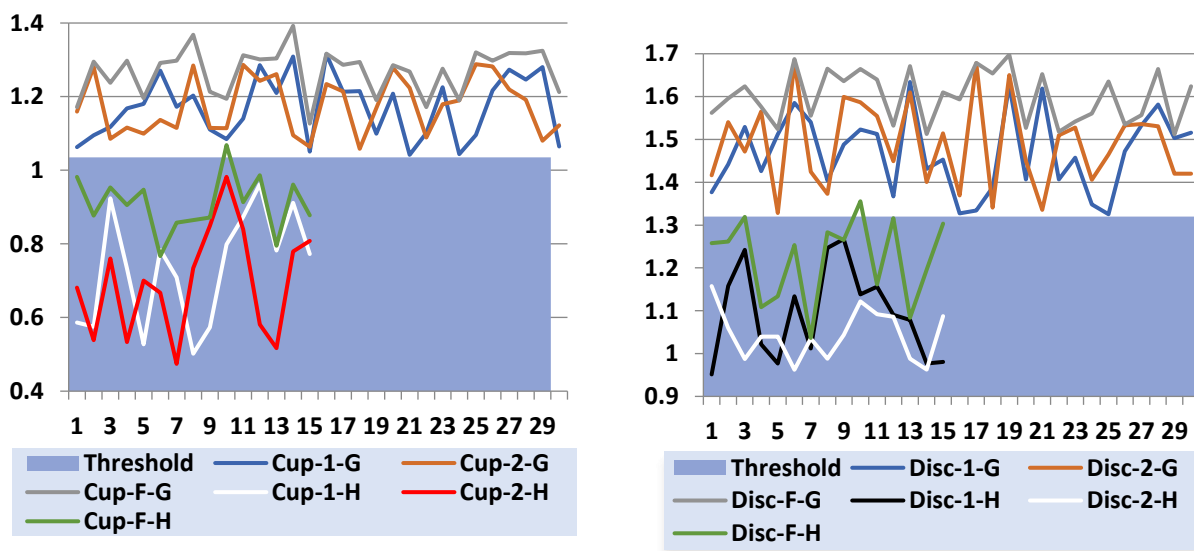


Figure.6 Calculated FD values on results of thresholding (Cup/Disc-1), K-means (Cup/Disc-2) and image fusion (Cup/Disc-F) techniques

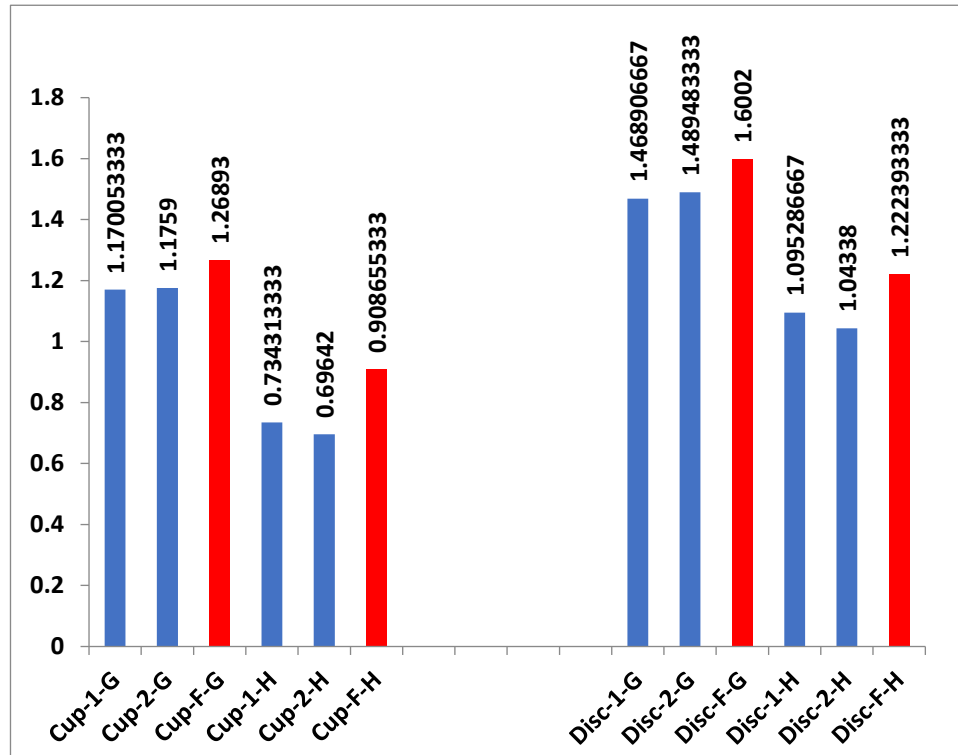


Figure.7 Average FD values calculated on results of thresholding, K-means and image fusion techniques

4. CONCLUSION

Early detection and diagnosis of glaucoma in everyday practice is more essential in order to ensure potential benefits for early treatment. In this work, new technique is developed to improve glaucoma evaluation. Calculating the accurate cup and disc areas using single technique in glaucoma evaluation is a challenging task. Thus, outputs of two feasible methods (thresholding and k-means) are combined to obtain accurate cup and disc areas, which in turn supports better glaucoma identification. A novel parameter called Fractal Dimension is calculated on cup and disc areas using box counting technique. Results show the proposed system is efficiently classified the images. This illustrates the image fusion technique is better approach to improve the accuracy of glaucoma detection. The proposed method is tested on HRF Dataset and

provided better outcomes as compared to existing approaches. The results obtained are correlated with the results of the ophthalmologist and provided accuracy of 97%. Therefore, the proposed system can be used for early detection of glaucoma and as the decision support system for ophthalmologists.

CONFLICT OF INTERESTS

The author(s) declare that there is no conflict of interests.

REFERENCES

- [1] G. Lazcano-Gomez, M. de los A. Ramos-Cadena, M. Torres-Tamayo, et al. Cost of glaucoma treatment in a developing country over a 5-year period, *Medicine*. 95 (2016), e5341.
- [2] P. Pravitra, T. C. Manjunath, D. Lamani, et al. Different clinical parameters to diagnose glaucoma disease: a review, *Int. J. Computer Appl.* 115 (2015), 42–46.
- [3] S. Chandrappa, L. Dharmanna, K.I.R. Neetha, Automatic Elimination of Noises and Enhancement of Medical Eye Images through Image Processing Techniques for better glaucoma diagnosis, in: 2019 1st International Conference on Advances in Information Technology (ICAIT), IEEE, Chikmagalur, India, 2019: pp. 551–557.
- [4] S. Chandrappa, D. Lamani, S. Jagadeesha, R. Kumar, Segmentation of retinal nerve fiber layer in optical coherence tomography (OCT) images using statistical region merging technique for glaucoma screening, *Int. J. Computer Appl.* 128 (2015), 32–35.
- [5] L. Dharmanna, S. Chandrappa, T.C. Manjunath, G. Pavithra, A novel approach for diagnosis of glaucoma through optic nerve head (ONH) analysis using fractal dimension technique, *Int. J. Mod. Educ. Computer Sci.* 8 (2016), 55–61.
- [6] G. Pavitra, T.C. Manjunath, D. Lamani, Automated diagnose of neovascular glaucoma disease using advance image analysis technique, *Int. J. Appl. Inform. Syst.* 9 (2015), 1–6.
- [7] F. Ajesh, R. Ravi, G. Rajakumar, Early diagnosis of glaucoma using multi-feature analysis and DBN based classification, *J. Ambient Intell. Human Comput.* 12 (2021), 4027–4036.
- [8] J. Carrillo, L. Bautista, J. Villamizar, J. Rueda, M. Sanchez, D. rueda, Glaucoma Detection Using Fundus

- Images of The Eye, in: 2019 XXII Symposium on Image, Signal Processing and Artificial Vision (STSIVA), IEEE, Bucaramanga, Colombia, 2019: pp. 1–4.
- [9] G. An, K. Omodaka, K. Hashimoto, S. Tsuda, Y. Shiga, N. Takada, T. Kikawa, H. Yokota, M. Akiba, T. Nakazawa, Glaucoma Diagnosis with Machine Learning Based on Optical Coherence Tomography and Color Fundus Images, *J. Healthcare Eng.* 2019 (2019), 4061313.
- [10] U.R. Acharya, S. Bhat, J.E.W. Koh, S.V. Bhandary, H. Adeli, A novel algorithm to detect glaucoma risk using texton and local configuration pattern features extracted from fundus images, *Computers Biol. Med.* 88 (2017), 72–83.
- [11] S. Simonthomas, N. Thulasi, P. Asharaf, Automated diagnosis of glaucoma using Haralick texture features, in: *International Conference on Information Communication and Embedded Systems (ICICES2014)*, IEEE, Chennai, India, 2014: pp. 1–6.
- [12] A. Pal, M.R. Moorthy, A. Shahina, G-Eyenet: A convolutional autoencoding classifier framework for the detection of glaucoma from retinal fundus images, in: *2018 25th IEEE International Conference on Image Processing (ICIP)*, IEEE, Athens, 2018: pp. 2775–2779.
- [13] J.J. Gómez-Valverde, A. Antón, G. Fatti, et al. Automatic glaucoma classification using color fundus images based on convolutional neural networks and transfer learning, *Biomed. Opt. Express.* 10 (2019), 892-913.
- [14] A.C. de Moura Lima, L.B. Maia, R.M. Pinheiro Pereira, et al. Glaucoma diagnosis over eye fundus image through deep features, in: *2018 25th International Conference on Systems, Signals and Image Processing (IWSSIP)*, IEEE, Maribor, Slovenia, 2018: pp. 1–4.
- [15] A. Li, Y. Wang, J. Cheng, J. Liu, Combining multiple deep features for glaucoma classification, in: *2018 IEEE International Conference on Acoustics, Speech and Signal Processing (ICASSP)*, IEEE, Calgary, AB, 2018: pp. 985–989.
- [16] Y. Chai, H. Liu, J. Xu, Glaucoma diagnosis based on both hidden features and domain knowledge through deep learning models, *Knowl.-Based Syst.* 161 (2018), 147–156.
- [17] B. Mandelbrot, *The fractal geometry of nature*, W.H. Freeman and Company, San Francisco, (1983).
- [18] High-Resolution Fundus (HRF) Image Database. Germany: FAU. Available from:
<https://www5.cs.fau.de/research/data/fundus-images/>

- [19] https://en.wikipedia.org/wiki/S%C3%B8rensen%E2%80%93Dice_coefficient
- [20] A. Baratloo, M. Hosseini, A. Negida, G. El Ashal, Part 1: simple definition and calculation of accuracy, sensitivity and specificity, *Emergency*, 3 (2015), 48–49.
- [21] R. Besenczi, J. Tóth, A. Hajdu, A review on automatic analysis techniques for color fundus photographs, *Comput. Struct. Biotechnol. J.* 14 (2016), 371–384.